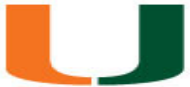

# Carotid Body Stimulator Surgical Considerations

UNIVERSITY  
OF MIAMI



Tony Shao MD, RPVI  
Assistant Professor of Surgery  
Division of Vascular Surgery  
Department of Surgery  
Miller School of Medicine  
University of Miami

2/2/23

UNIVERSITY  
OF MIAMI



**Disclosures:**

None

---

# Pre-op Evaluation

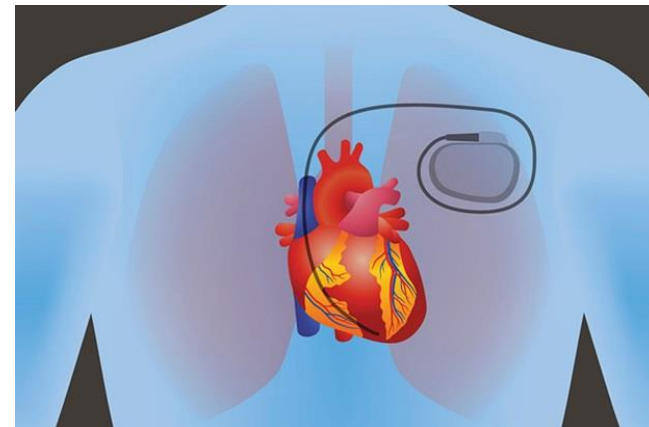
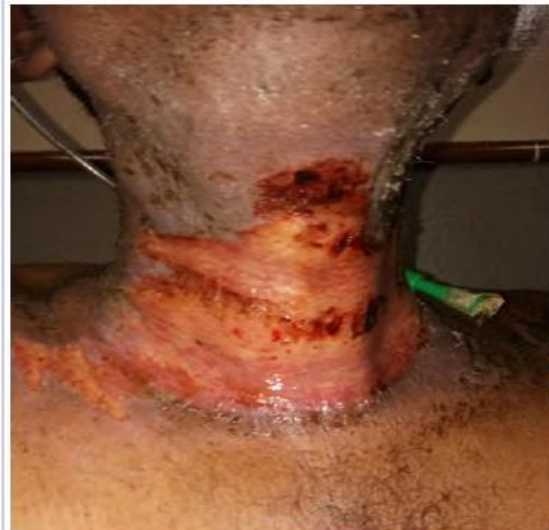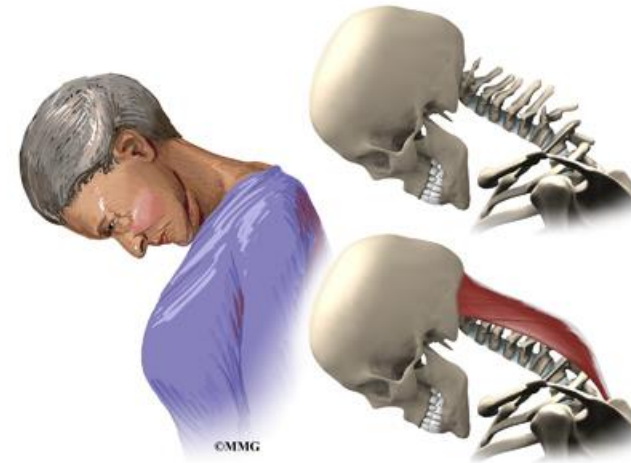
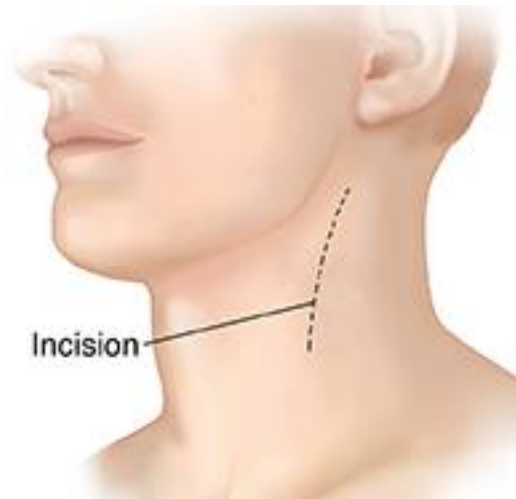1. **Confirm indication**
2. **History and physical exam**
3. **Carotid duplex and other pertinent imaging**

---

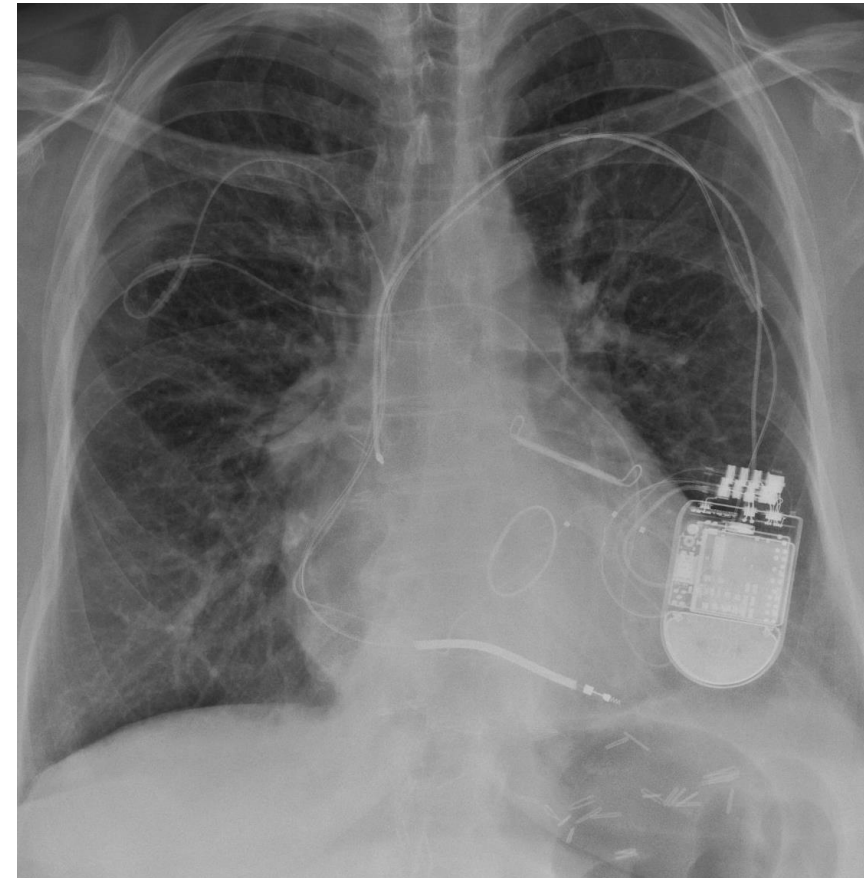
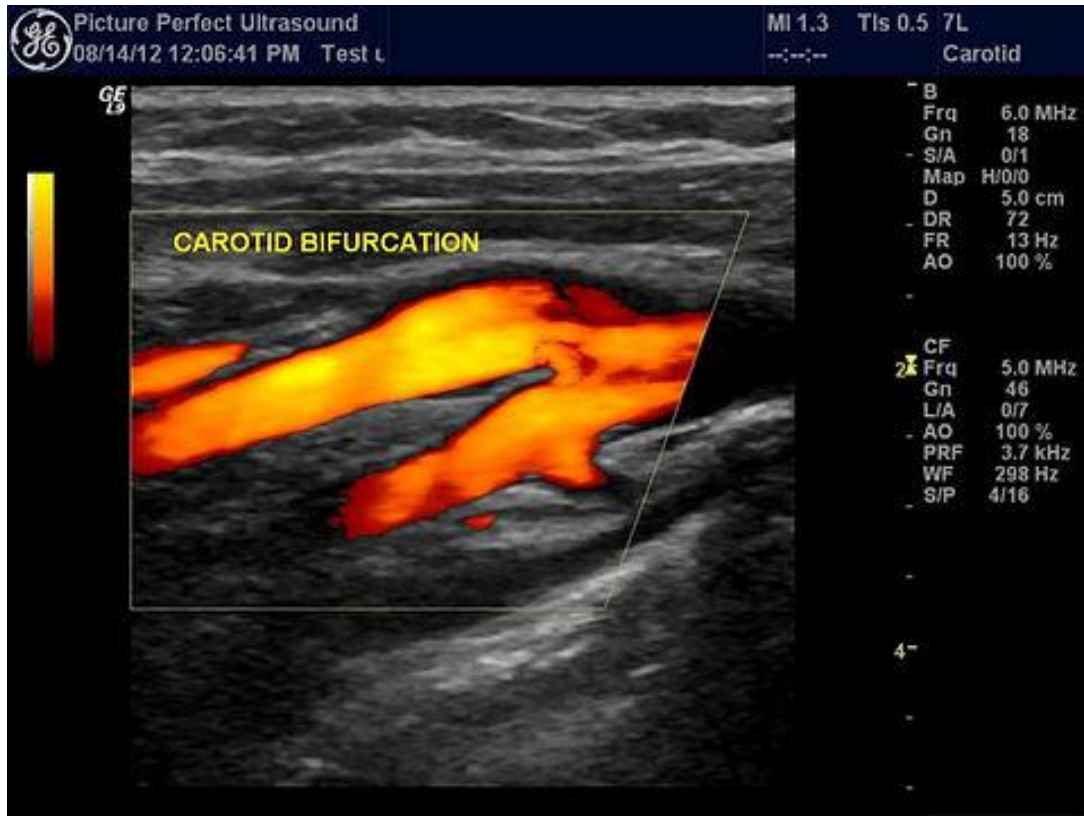# History

- Prior neck surgery
  - Previous carotid endarterectomy / carotid stenting
  - Neck dissection
- History of neck radiation
- Previous surgery involving the upper chest
- Degenerative cervical spine disease
- Previous CVA / TIA
- Previous or current devices
  - AICD
  - CRT
  - PPM

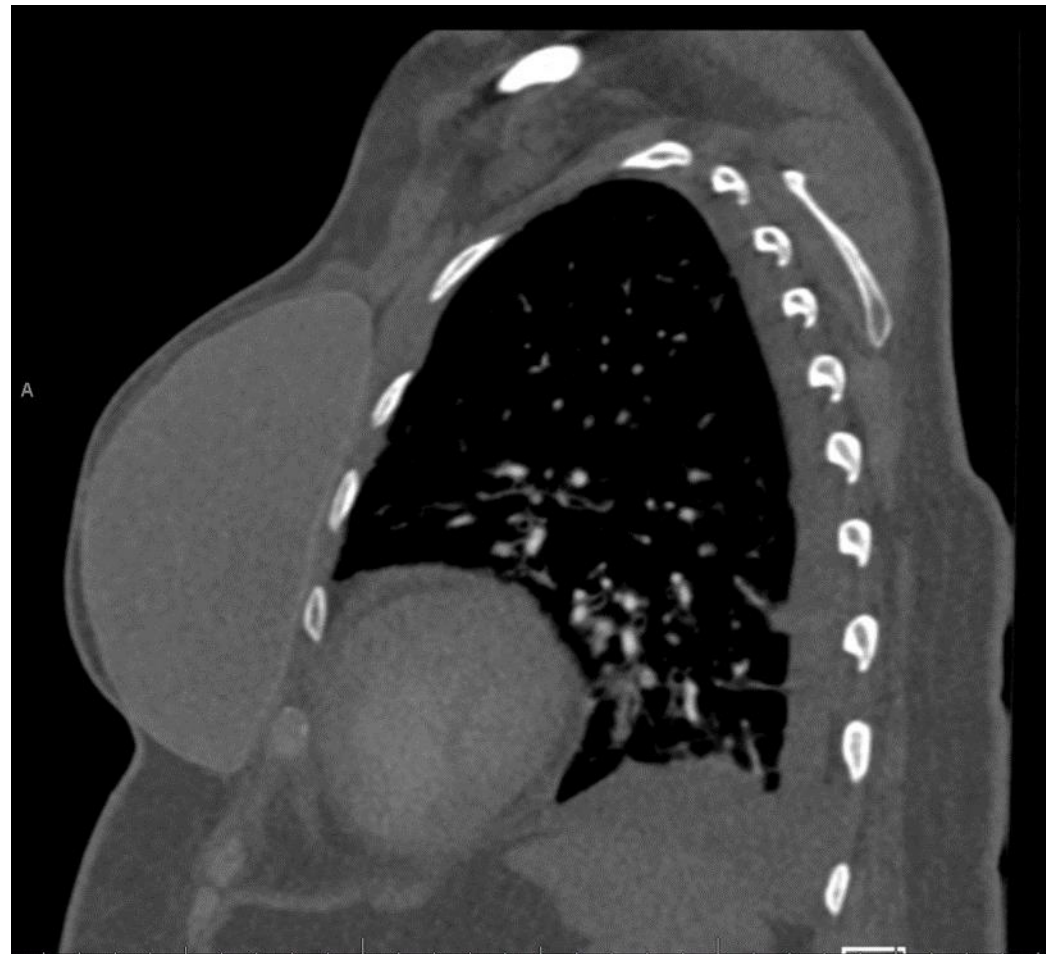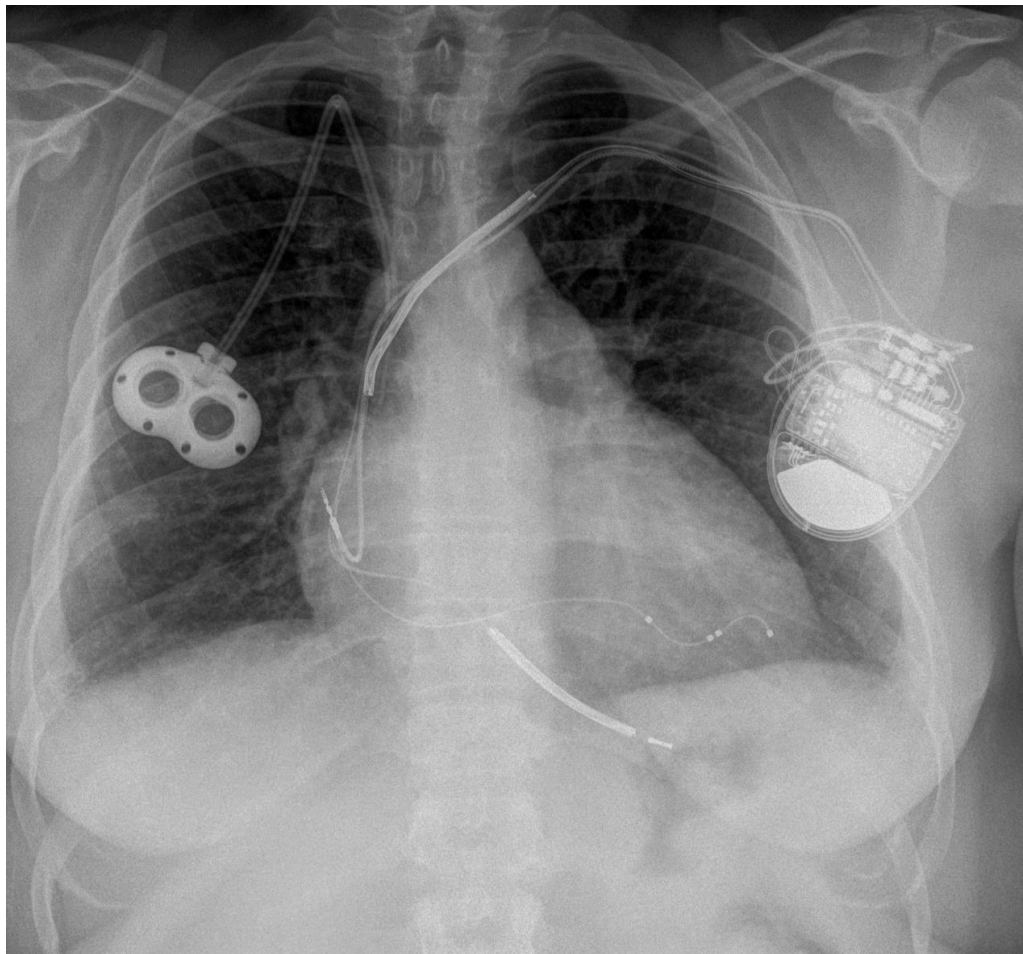
# Physical exam



# Imaging

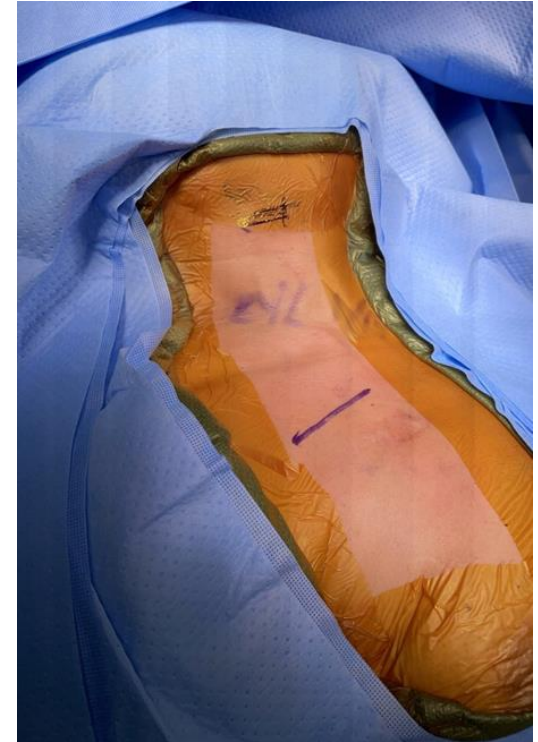

# Imaging



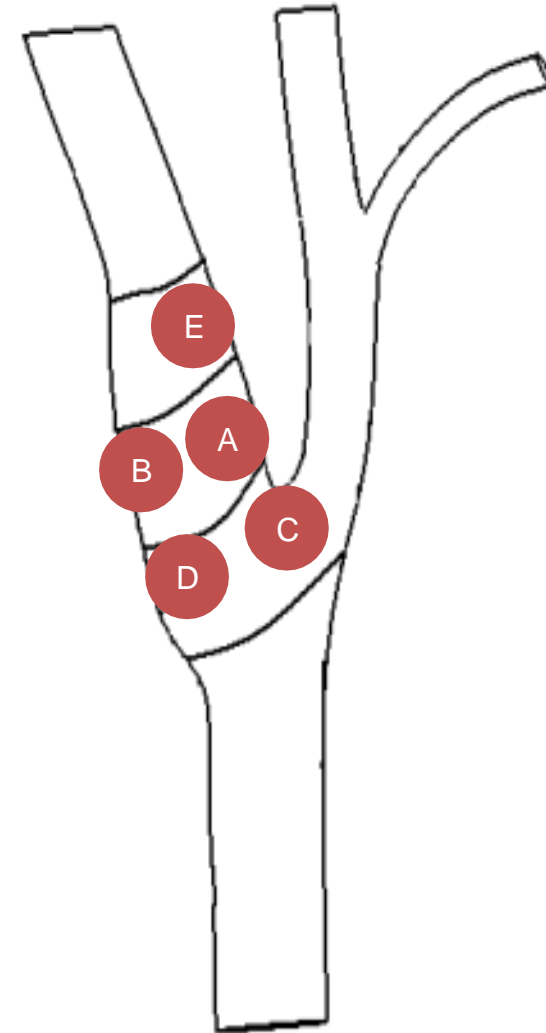
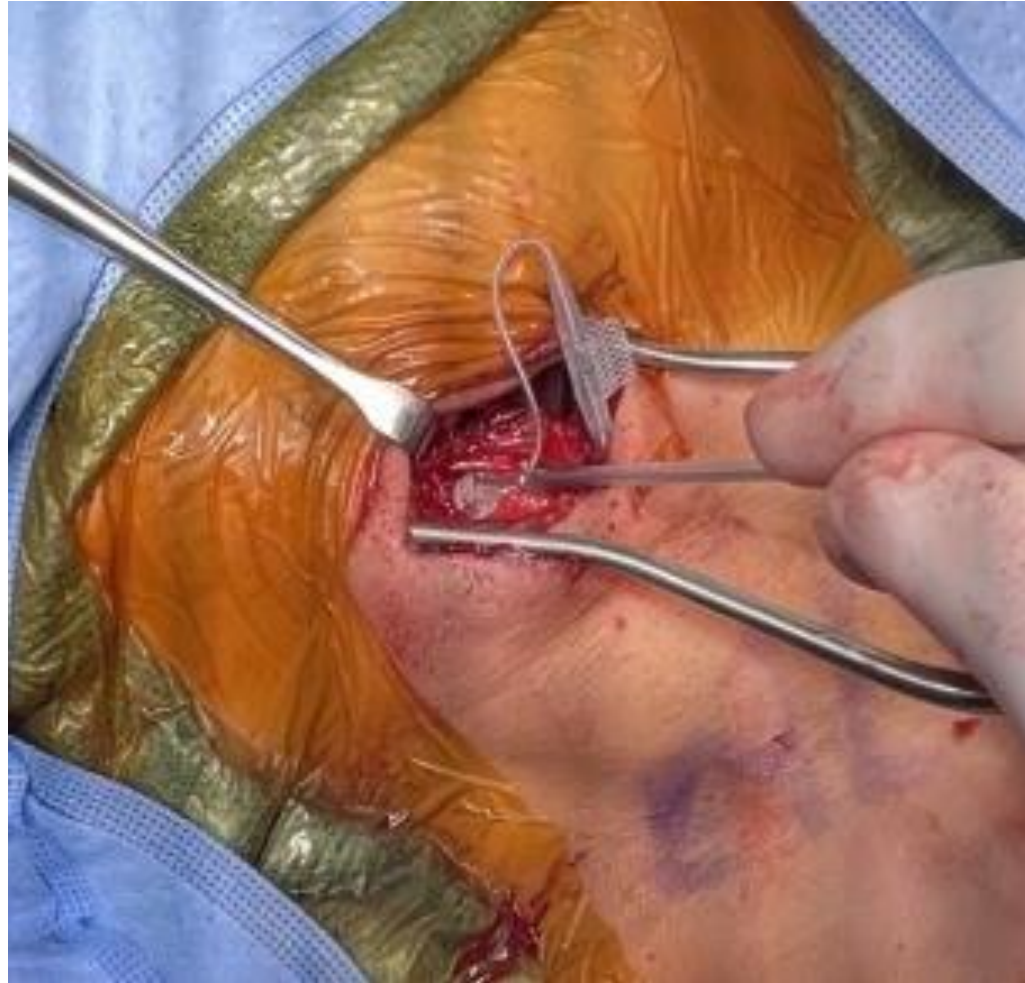# Intra-operative

- Touch base with anesthesia colleagues
  - Avoid certain anesthetic agents
- General Anesthesia
- Arterial line
- Large bore PIVs
- Identify the carotid bifurcation to plan the skin incision using ultrasound





# Intra-operative



---

# Post-op

- Patient typically can be discharged home same day
- Post-op visit within 2 weeks
  - Check the incisions
    - Infections
    - Skin dehiscence
- Periodic follow up for titration of therapy

---

Thank you