FACULTAD DE MEDICINA
UNIVERSIDAD DE CHILE

CLÍNICA Alemana

Ministerio de Salud
Gobierno de Chile

INSTITUTO NACIONAL DEL TORAX

Tricuspid valve regurgitation after heart transplantation, novelty treatment

Dr. Jorge Sandoval , Dr. Christian Dauvergne , Dr. Franco Appianni Dr. Oscar Cuevas, Dra. Pabla Cataldo, Dr. Mario Araya

Instituto Nacional del Tórax

Clínica Alemana

Universidad de Chile

MIAMI 2023 VALVES
MiamiValves.org

Potential conflicts of interest

I do not have any potential conflict of interest to report

CLINICAL CASE

- 65 Years old male
- Medical history:
  - Dilated myocardiopathy
  - 2010, Heart transplantation
  - 2021 Humoral rejection with numerous endomyocardial biopsies.
    - Atrial fibrilation,
    - Pacemaker DDD (sick sinus).
    - RV disfunction with severe tricuspid regurgitation
- Medicaction:
  - Tacrolimus 2mg BID, mycophenolate 750mg BID, Atorvastatin 20mg QD, Coumadin, Carvedilol 6,25mg BID, Furosemida 40mg BID, spironolactone 25mg QD.
- Clinical presentation:
  - Dyspnea (Functional class III) and edema.
  - Pro BNP 825 pg/dl

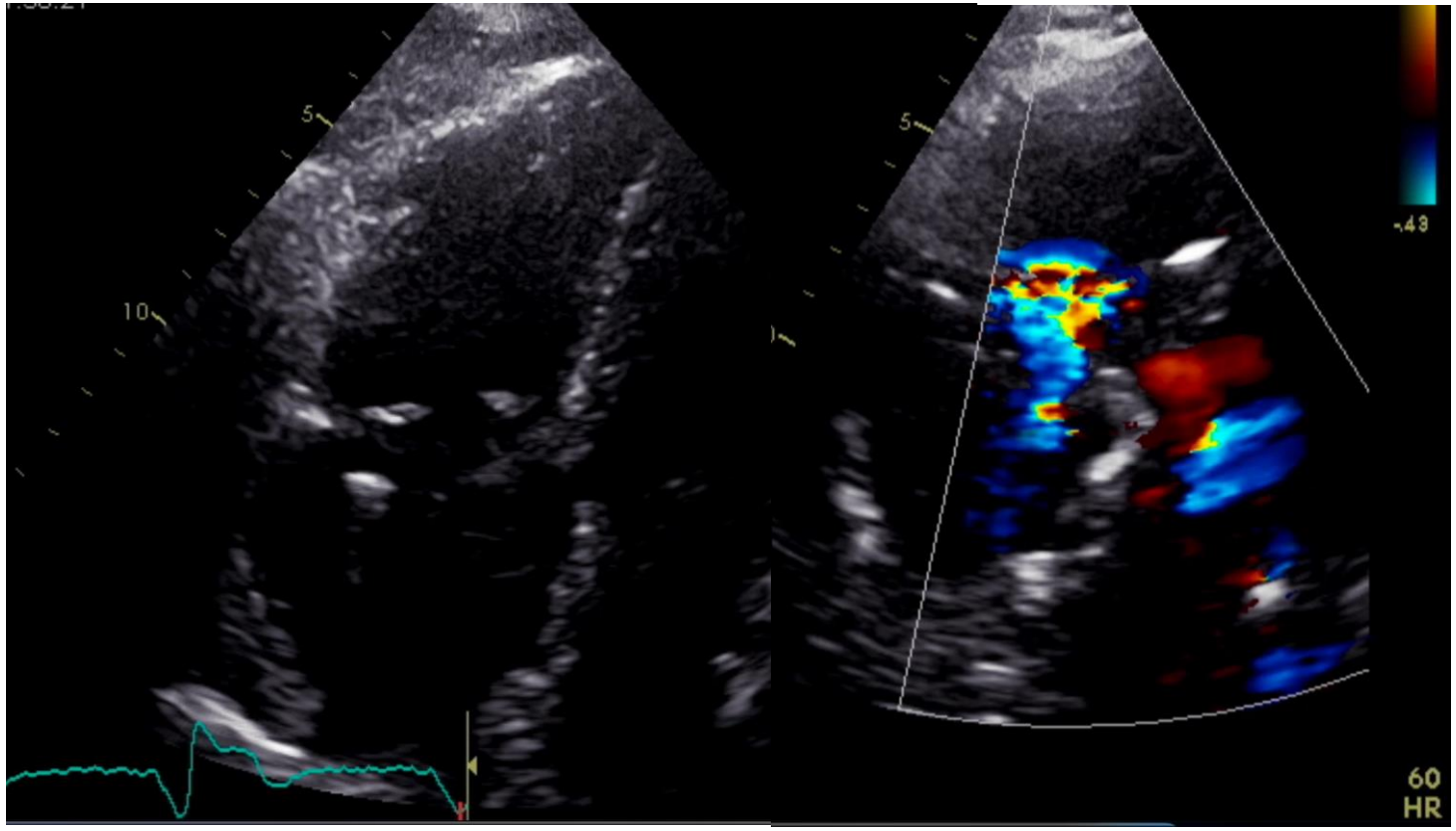

Owing to high risk (Triscore: 5 -> 14% mortality), previous cardiac surgery and pacemaker the heart team opted for percutaneus resolution.

MIAMI 2023 VALVES
MiamiValves.org

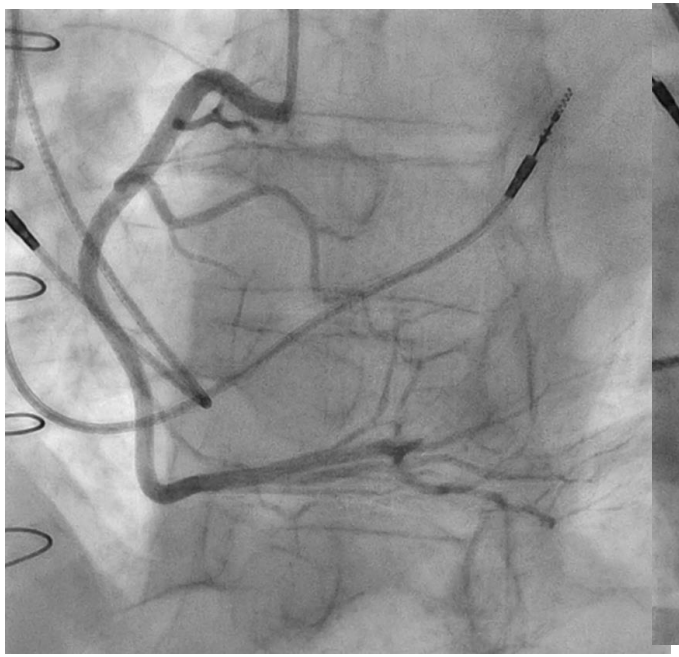

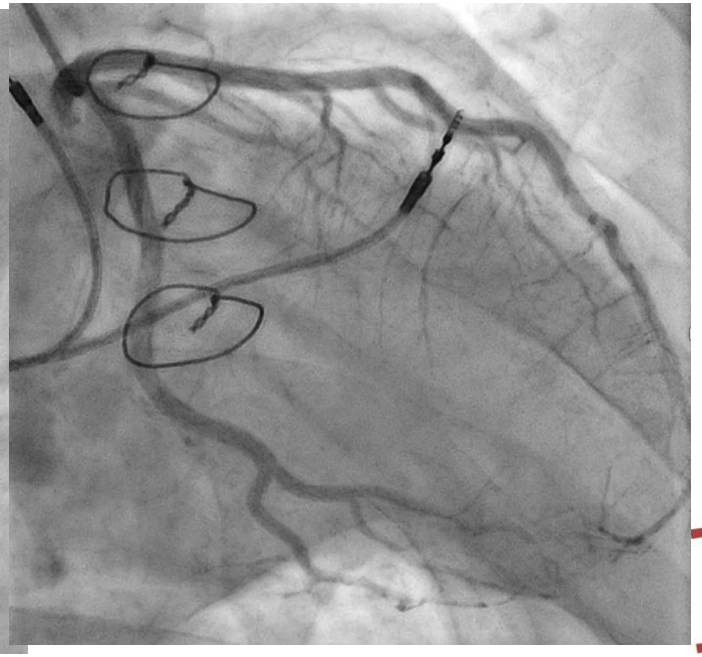

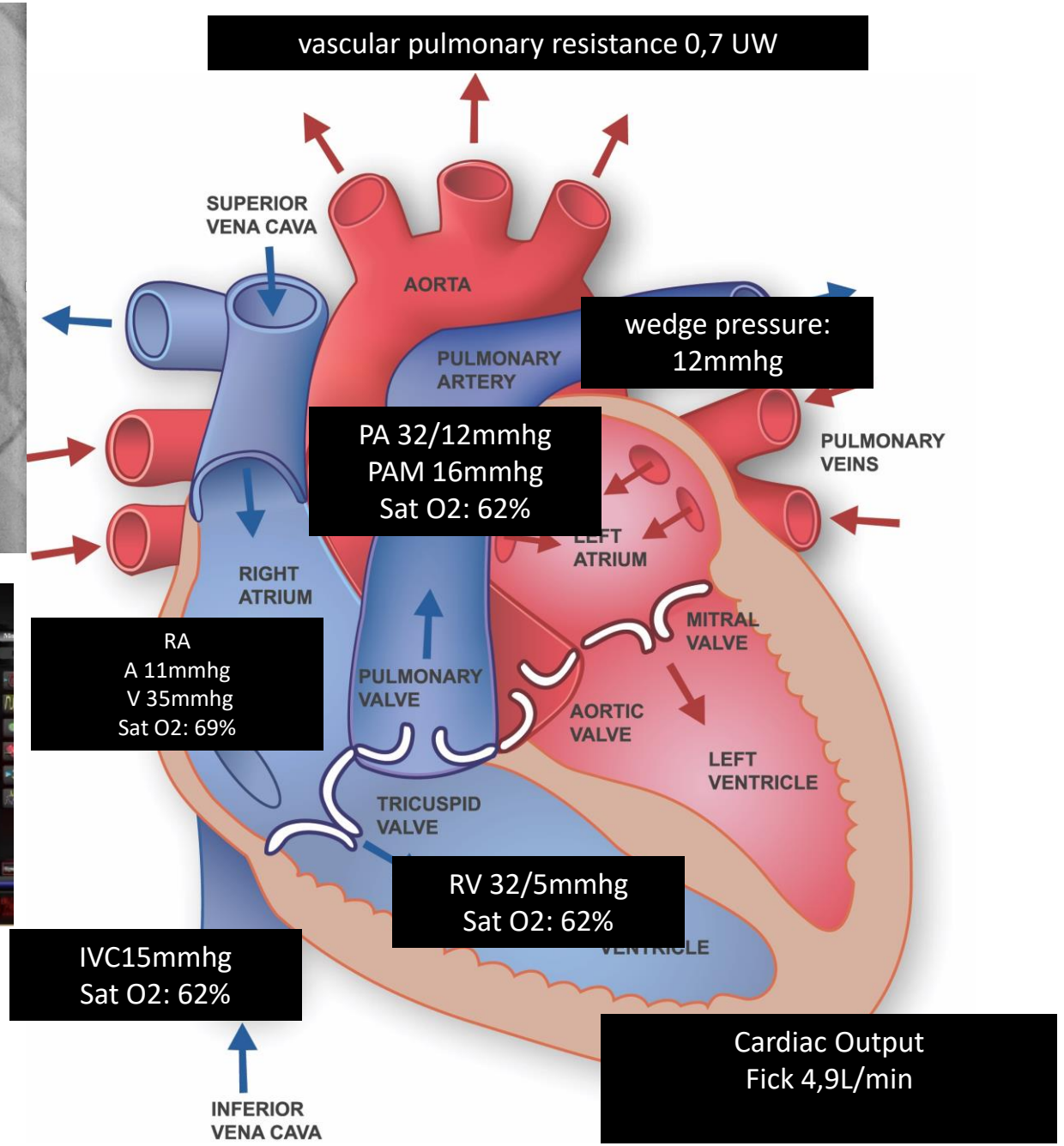

MIAMI 2023 VALVES
MiamiValves.org

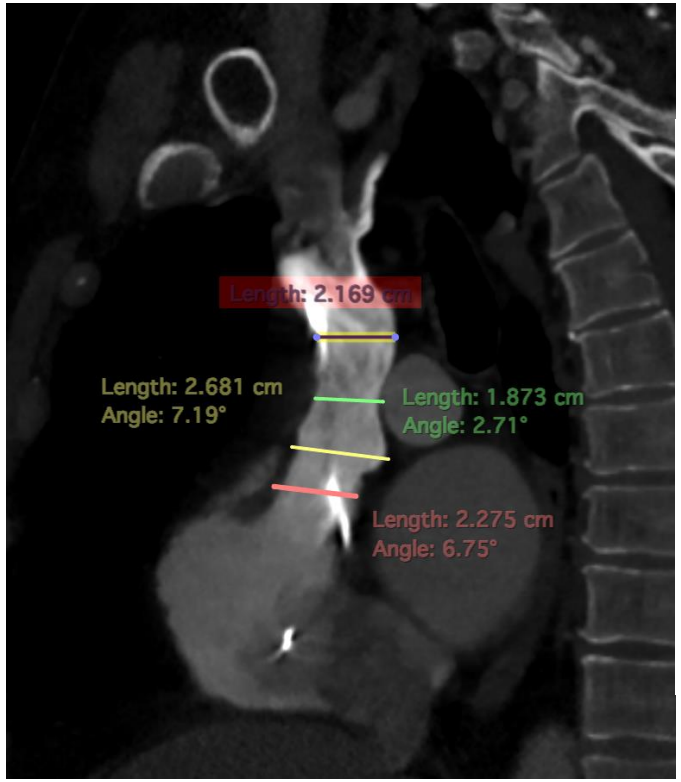

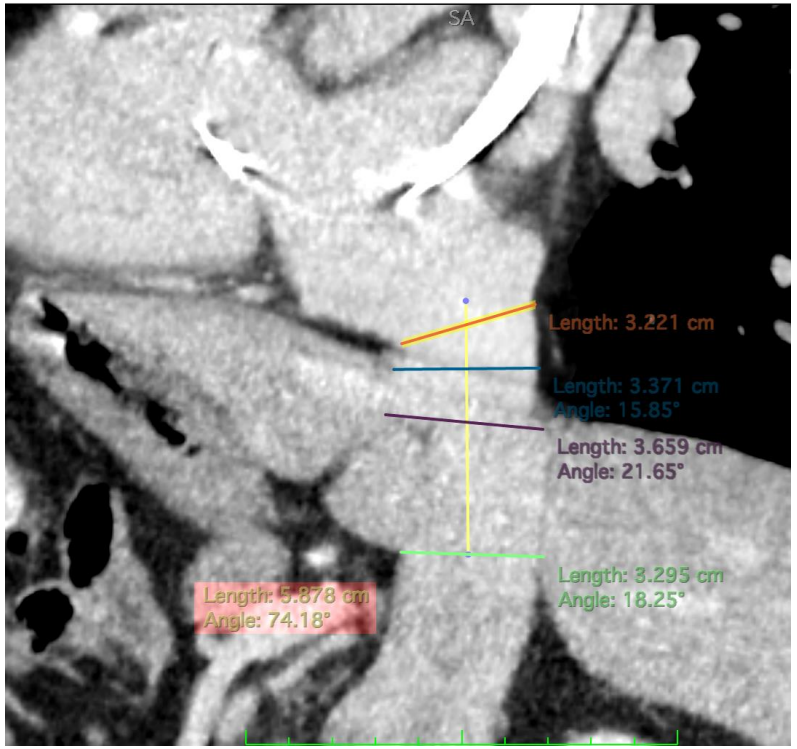

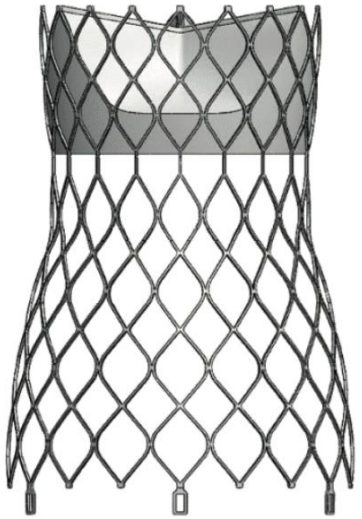

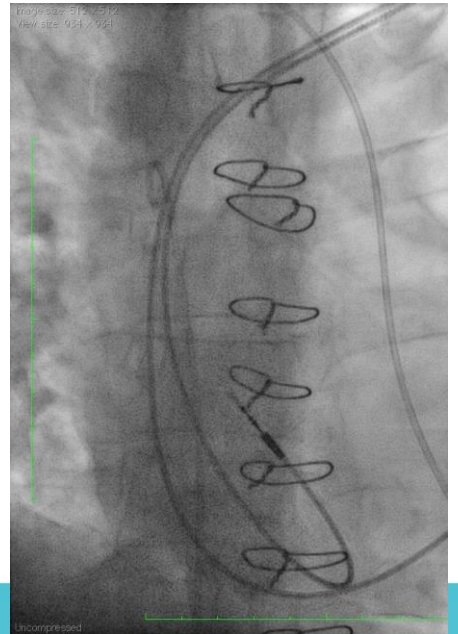

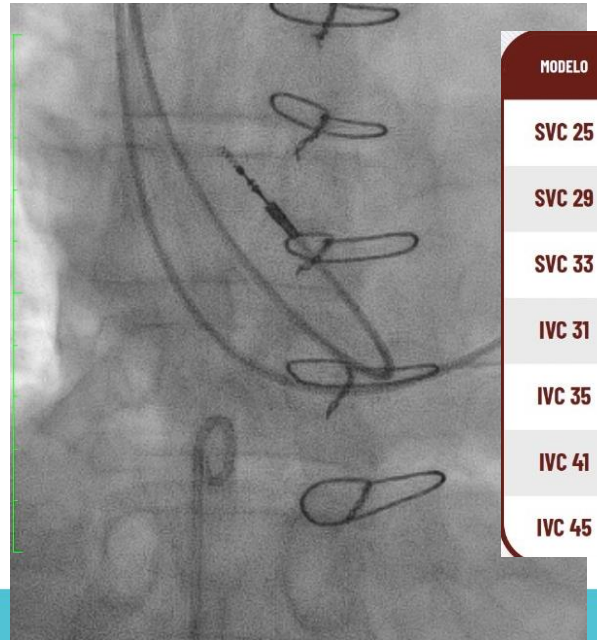

MODELO	TAMANHO DA VÁLVULA	DIÂMETRO PROXIMAL	DIÂMETRO DISTAL	DIÂMETRO MÁXIMO	COMPRIMENTO APÓS A IMPLANTAÇÃO
SVC 25	25	25	20	35	66,60
SVC 29	29	29	20	40	69,10
SVC 33	33	33	20	45	72,11
IVC 31	31	34	38	38	65
IVC 35	35	38	47	47	65
IVC 41	41	44	55	55	65
IVC 45	45	49	60	60	70

MIAMI 2023 VALVES
MiamiValves.org

Procedure

- Local anesthesia
- Femoral Vein access
  - Left 6 Fr.
  - Rigth 6-18-24 Fr
- Heparin ACT

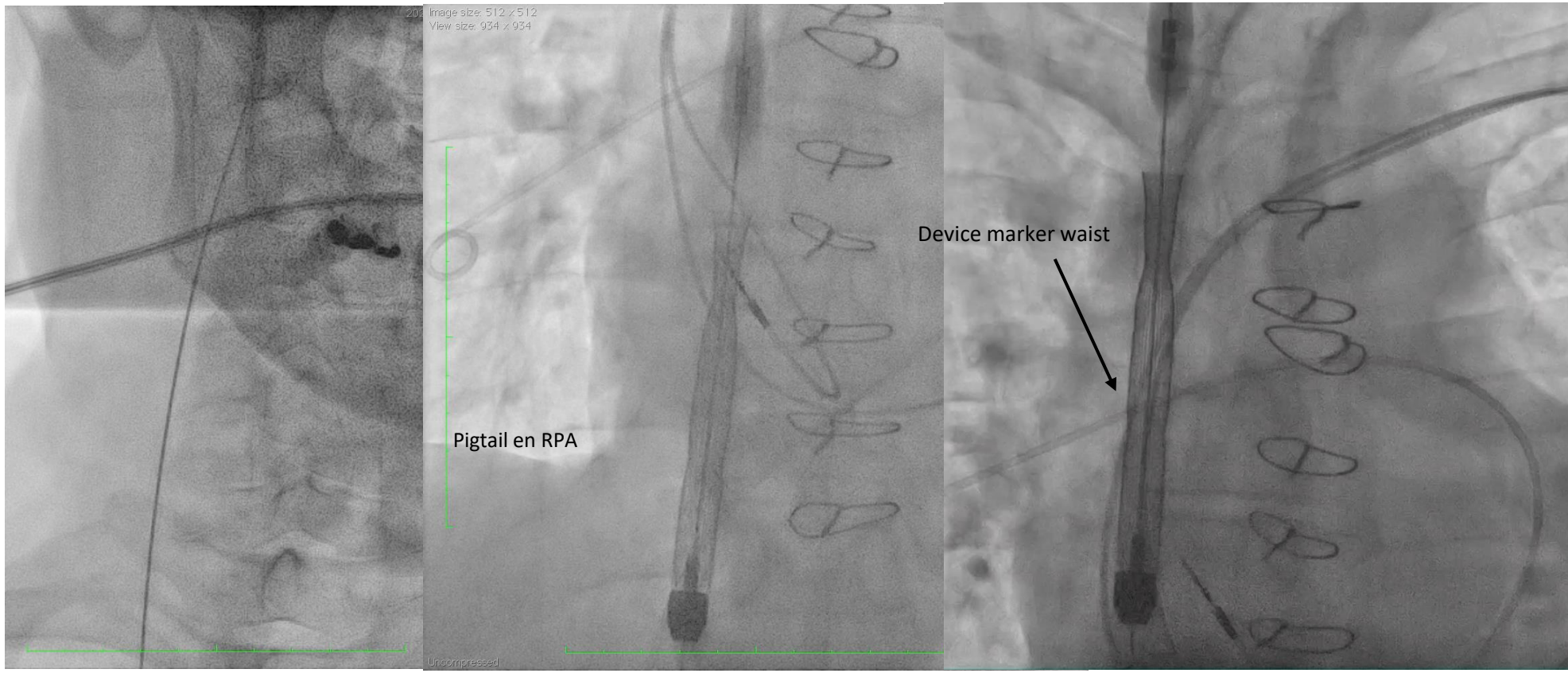

MIAMI 2023 VALVES
MiamiValves.org

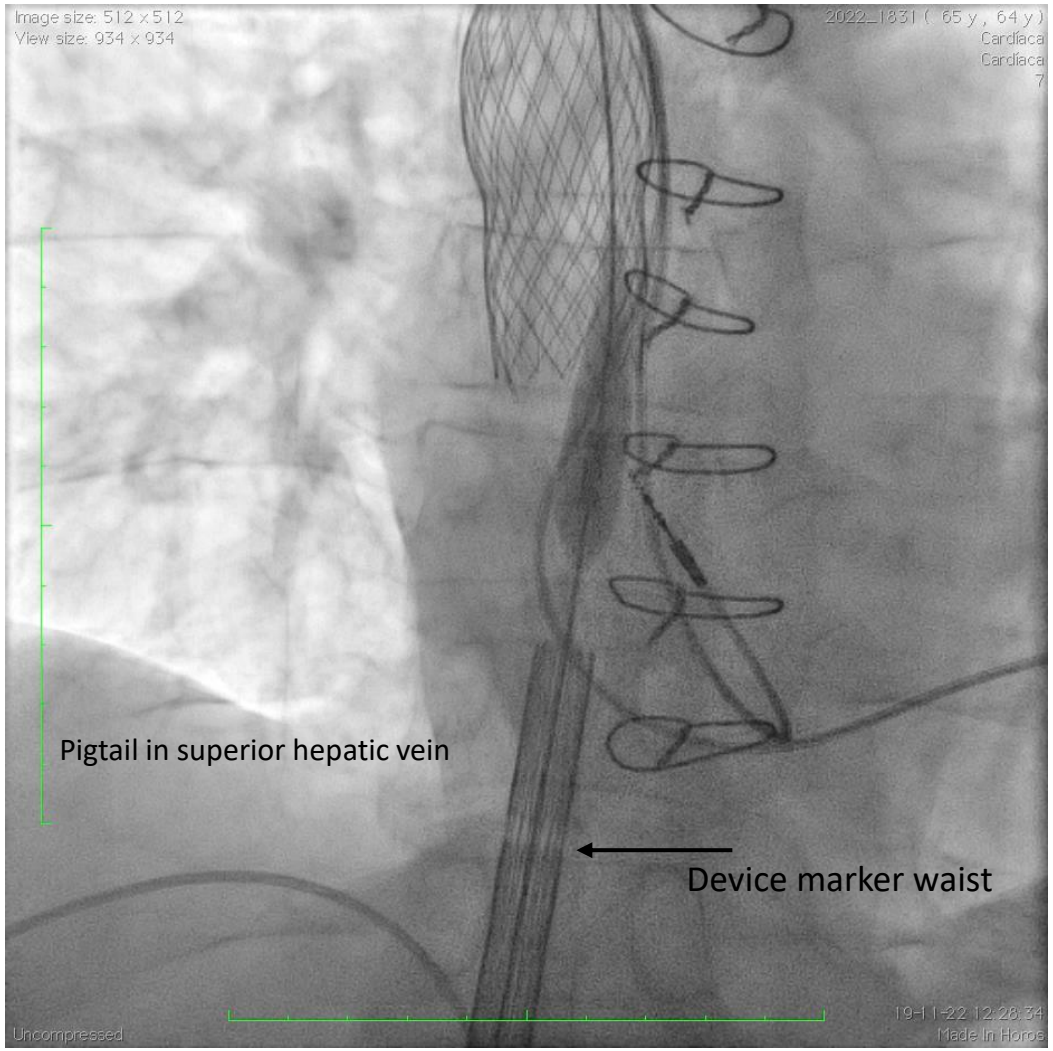

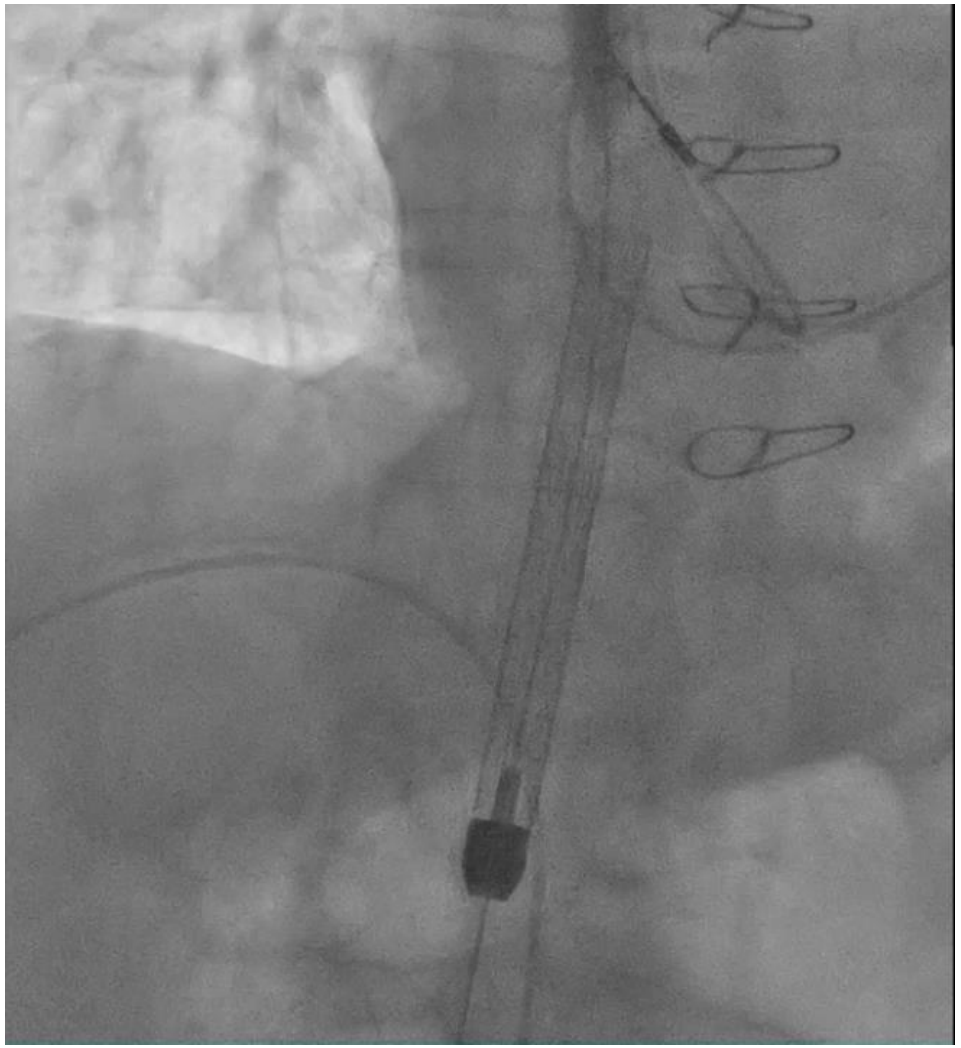

MIAMI 2023 VALVES
MiamiValves.org

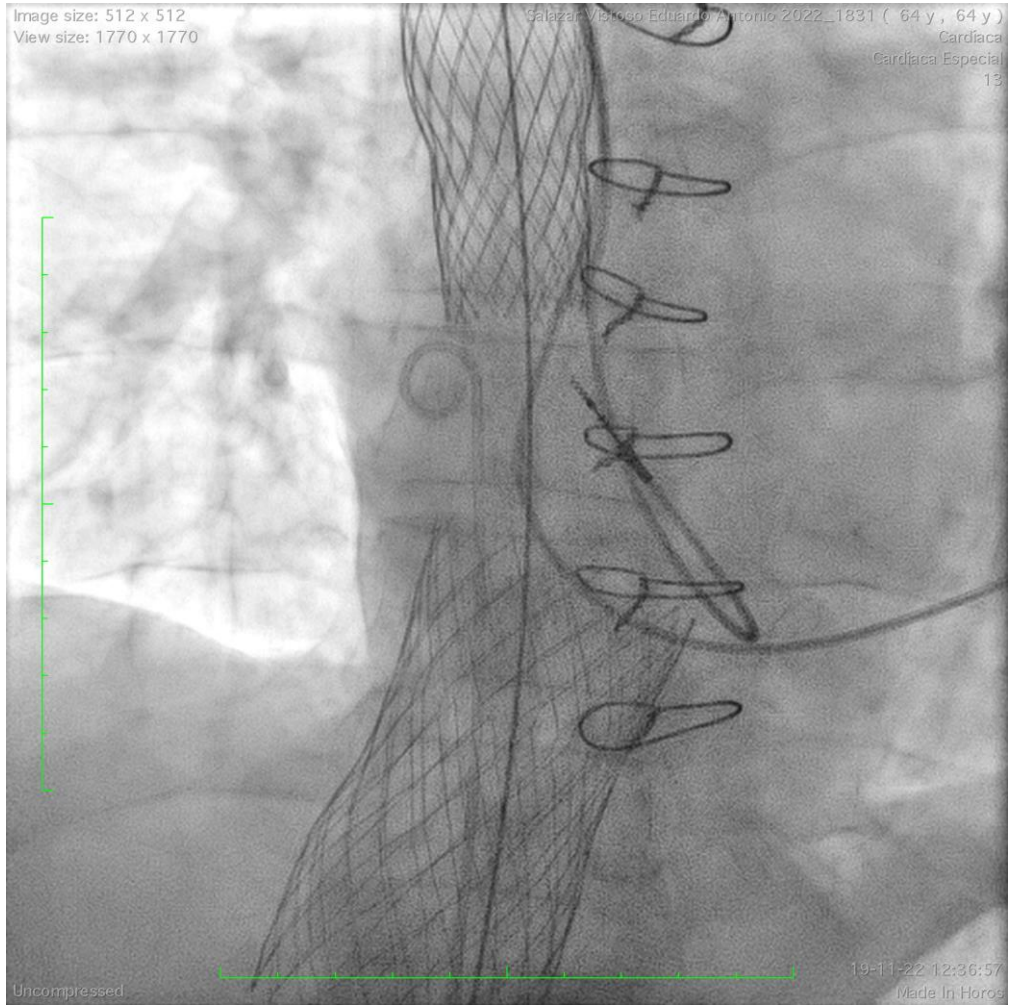

- Right shoulder pain
- No complications of vascular access.
- Pacemaker with normal impedance and threshold.
- two day home discharge
- titration of anticoagulation.
- titration of diuretics.
- No edema, no ascitis, no hepatomegaly,

MIAMI 2023 VALVES
MiamiValves.org

Follow up

- 3 Months
  - Functional class I.
  - No edema, no diuretics.
- Pro BNP : 216 pg/dl
- Echo:
  - RV diameter 46 mm
  - TAPSE 13mm
  - PAPs 35mmhg
  - Leaks -

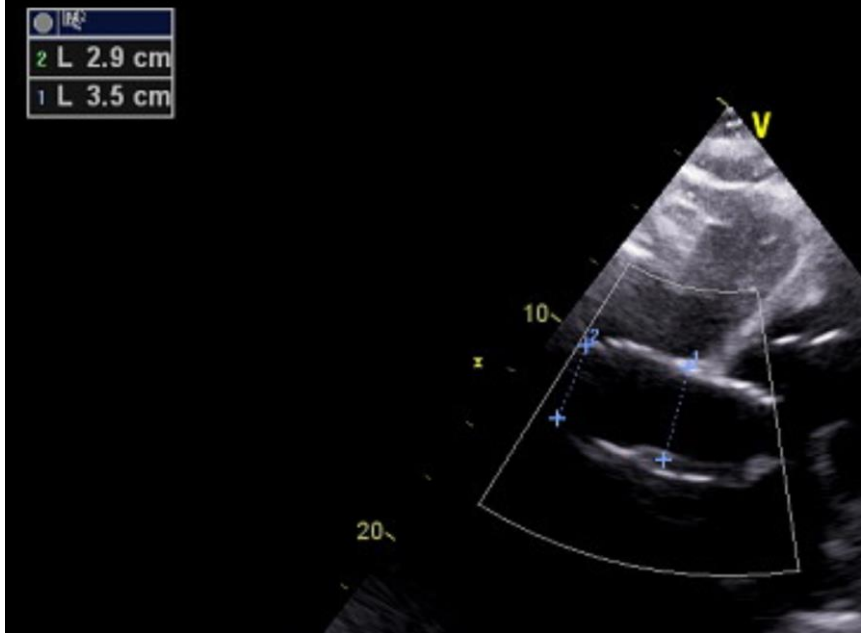

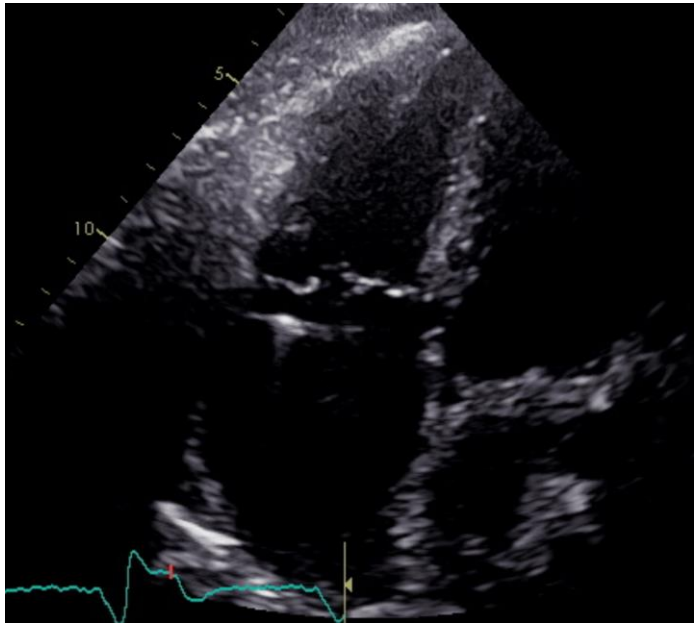

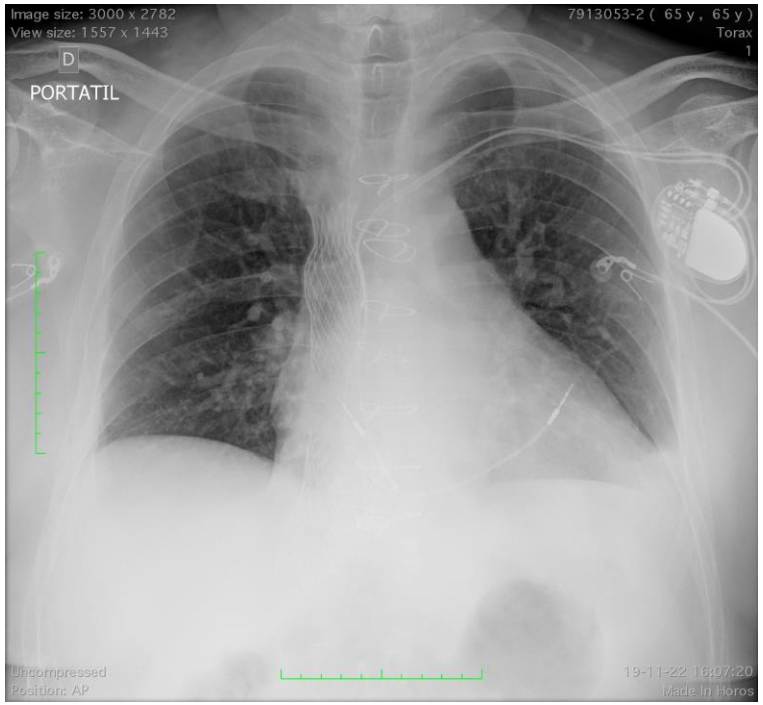

MIAMI 2023 VALVES
MiamiValves.org

Take message

- Tricuspid regurgitation is the most frequent valve disease after orthotopic heart transplant. Surgical corrections were not realized for a surgical high risk (reesternotomy and immunosuppressor)
- We report a case of successful percutaneous bicaval tricuspid valve repair for severe tricuspid regurgitation after 12 years of cardiac transplantation and pacemaker leads.
- The patient's symptoms improved, and follow-up echocardiogram showed reduction of right ventricle diameter and normalization of pro BNP
- Percutaneous tricuspid valve repair can be considered as an alternative option to conventional surgery for symptomatic severe tricuspid regurgitation in orthotopic heart transplant recipients.
- It´s necessary more information about the structural deterioration of the valve in the future



MIAMI 2023 VALVES

MiamiValves.org